

## Historical vignette

# Treatment of aneurysms with wires and electricity: a historical overview

**KHAWAR SIDDIQUE, M.D., JORGE ALVERNIA, M.D., KENNETH FRASER, M.D.,  
AND GIUSEPPE LANZINO, M.D.**

*Departments of Neurosurgery and Radiology, University of Illinois College of Medicine, Peoria, Illinois*

✓✓ Endovascular treatment of aneurysms has only recently become an accepted therapeutic modality. Nonetheless, treatment of aneurysms with the aid of various foreign bodies such as needle and wire insertion with or without electrical current has been reported since the first half of the 19th century. In 1832 Phillips induced clot formation in the femoral and carotid arteries of dogs by leaving needles in the arteries for variable lengths of time. Simultaneously, in France, Velpeau had proposed using “l’acupuncture des arteres dans le traitement des anevrismes.” Later, Phillips and Pelrequin connected the offending needles to a source of electrical current in an attempt to increase thrombus formation and aneurysm occlusion. Subsequently, Moore introduced the concept of packing the aneurysm with wire inserted through a needle transfixed to the vessel wall. To this method, Corradi added electrical current. Widely known as the Moore–Corradi technique, it was used in ensuing years with variable success. The early phase of endovascular aneurysm treatment culminated when Blake-more and Moore treated a case of symptomatic cavernous sinus aneurysm by passing wire through the patient’s orbit. These pioneering cases combined with technological advances in the diagnosis of intracranial aneurysms paved the way for further refinements in coil embolization of aneurysms.

**KEY WORDS • endovascular treatment • aneurysm • neurosurgical history •  
electrothrombosis**

**T**HE development of the endovascular treatment of aneurysms is a classic story of medical and technological advances leading to improved treatments. This process began in the first half of the 19th century when adventurous and ingenious physicians sought alternative therapies because of their frustration with conventional aneurysm treatments. Early attempts in aneurysm occlusion involved the use of foreign objects to fill the aneurysm sac and direct electrical current to induce aneurysm thrombosis in animal models and patients. In this article, we review early (until the first half of the last century) nonsurgical aneurysm treatments that have paved the way to modern endovascular techniques.

### *Aneurysm Treatment in the Early 19th Century*

At the beginning of the 19th century, satisfactory methods for the treatment of large aneurysms were not available. Proximal pressure had been applied for aneurysms of the abdominal aorta, but with limited success and complications such as gangrene and ischemia. Moreover, this method was not applicable for lesions located in internal areas such as the thoracic aorta.<sup>16</sup> Hunterian ligation, another commonly used treatment, was appropriate for aneurysms of small- and intermediate-size vessels, but proved universally fatal in patients with aortic aneurysms. Because of these limitations in surgical intervention, medical therapy, although rarely curative, was generally accepted as the first

line of treatment for aortic aneurysms. The most commonly used medicinal compound was systemically administered potassium iodide. Although indicated mainly for syphilitic aneurysms, this agent was used to remedy many types of lesions and was especially useful for alleviating aneurysm-induced pain.<sup>17</sup> The mechanism of pain reduction was postulated to be enhanced thrombosis of the aneurysm through reduction of heart rate and blood pressure.<sup>17</sup> Other pharmacological and nonpharmacological substances used in an attempt to ablate aneurysms included vinegar, iron perchloride solution, alcohol, zinc chloride, gelatin, sodium chloride, and ergot salts.<sup>26</sup> Hypothermia also was used to reduce inflammatory congestion and thereby promote thrombosis; however, ice packing, especially as an adjunct to other treatments such as the injection of gelatin, received little enthusiasm and had already been abandoned by the early 19th century.<sup>17</sup>

### *Aneurysm Treatment With Wires and Other Foreign Bodies*

At the end of the 18th century, Sir E. Herne coagulated an iliac aneurysm by introducing heated needles into the sac.<sup>24</sup> In 1832 Phillips wished to cure aneurysms without resorting to existing treatments such as ligation. He reasoned that “if I could devise any mode by which inflammation might be excited in the parietes of an artery, that inflammation would be succeeded by coagulation, and a consequent

## Treatment of aneurysms with wires and electricity

obliteration of the artery.”<sup>22</sup> With the aid of femoral and carotid arteries in dogs, he studied clot formation by the direct insertion of fine needles through vessel walls. He observed that the “introduction of a foreign body into an artery may occasion the formation of a clot or coagulum, from the blood circulating in that artery . . . [and] . . . that arteries may be obliterated with safety and certainty by the introduction into them of [the] foreign body.”<sup>22</sup> Simultaneously, in Paris, the famous French surgeon Velpeau was conducting similar coagulation experiments but with larger pins.<sup>30</sup>

The simple needle insertion procedures of Phillips and Velpeau produced unpredictable results and were thus abandoned. Macewen resurrected needle insertion toward the end of the 19th century, however. He reasoned that gradual lamellation and organization of white thrombus would follow the endothelial injury induced by introducing a needle into the aneurysm sac. In 1890 he applied the procedure to two aortic and one subclavian aneurysms. He introduced a long needle into the aneurysm sac, “where it remain[ed] twenty-four hours or more, during which the needle is moved sufficiently to scratch the intima and produce sufficient irritation to produce the formation of white or plaque-lukocyte-fibrin thrombi.”<sup>17</sup> He treated two cases successfully, but a patient in the third case died. Later, Weir and Page<sup>31</sup> performed a similar procedure in a thoracic aneurysm and scratched the inner wall of the lesion to promote thrombus. A thrombus failed to form and the patient later died of hemorrhage. Again, the technique was abandoned “on account of its uncertainty, the difficulty of limiting the effect of the puncture to the internal surfaces, and the fact that the aneurysm is often already lined with laminated clot.”<sup>17</sup> Hunner,<sup>16</sup> in his negative remarks, stated that “the process requires weeks to months for the thrombus formation, even in the most favorable sac.”<sup>16</sup>

In 1864 while at the Middlesex Hospital in England, C. H. Moore performed an autopsy on a sailor who had died of a gunshot wound to the chest. The autopsy revealed a metallic bullet within the ascending aorta embedded in fibrin. Moore wrote as follows:

The foreign body which according to our current knowledge would produce least irritation is wire. If a large quantity were coiled in an aneurysm, it would attract fibrin, as the twigs do in whipping freshly drawn blood, support the mass which it entangled, and lead to the cavity of the aneurysm being eventually filled. The wire might be passed in through a small cannula with care not to leave the last end in the minute wound, and not to direct a coil into the orifice of the artery.<sup>20,26</sup>

In his first case, Moore introduced 26 yards of coil into a thoracic aorta aneurysm and noticed a decrease in the pulsation and size of the aneurysm as well as an immediate reduction in the patient’s pulse from 116 to 92 beats per minute. Wire, as the theory stipulated, would promote thrombus and reduce flow into the aneurysm sac.<sup>6,20,24</sup> Moore considered wiring to be a palliative treatment and applicable only for accessible, superficial aneurysms, however. He correctly recognized the potential complications, some of which are pertinent even today. For instance, he predicted that subtotal packing of the coil would result in lower protection from hemorrhage and that distal embolization of the coil could occur from fragmentation of wire or thrombus. He suggested using fine wire, “which would be little stirred by either current to or fro.”<sup>26</sup> Although his first treated patient died of sepsis, Moore was encouraged by the

fact that at autopsy, “the interior of the tumor was filled, for the most part, with a fibrinous coagulum, enveloping and embedded in the coils of wire, and firmly adherent to the surrounding walls.” He described the “early results as strikingly confirming the main part of the theory and as affording . . . a substantial promise of advantage.”

Other investigators amended Moore’s techniques by developing coils from different materials. In the 1870s, Levis from Philadelphia and Bryant from London treated a subclavian and a popliteal aneurysm, respectively, with the aid of horsehair; both patients suffered aneurysm rupture days after treatment.<sup>24</sup> In March 1871, Domville inserted 14 in of iron wire into an aneurysm, but also failed to cure the disease. William Murray had better success: in May 1872 he reported on a gentleman who lived for 3 weeks with 21 ft of coil in an aortic aneurysm, only to succumb later. In 1877, buoyed by these reports, the Italian physicians Baccelli and Montenovesi used metal watch-springs to pack aneurysms. The springs were gilded to reduce oxidation and breaking, roughened by the fumes of osmic acid, and dipped in hydrochloric acid or iron perchloride. Success was limited, because many wires embolized to distant structures, including the left ventricle or aorta.<sup>24</sup> In 1886 Cayley placed 40 ft of steel wire by cannulation in a thoracic aorta aneurysm. Seven months later, the patient died of respiratory failure. Loreta of Bologna, Italy, used silvered copper wire inserted through a laparotomy to treat an abdominal aneurysm. The patient survived for 3 months, only to suffer a rupture at a site distal to the thrombosed aneurysm.<sup>24</sup> Later, Stewart used gold wire to pack a syphilitic aneurysm of the innominate artery; however, within 4 years, this patient died of cerebral thrombosis.<sup>28,29</sup>

In 1907 Boinet reported on 34 cases of thoracic and abdominal aneurysms treated by wire insertion alone; 30 patients died within a year of treatment.<sup>17</sup> In 1951, Linton<sup>18</sup> combined several previous techniques and reported on a series of 22 patients. His packing method made use of a laparotomy combined with a trocar system to directly visualize and place up to 965 ft of wire into aneurysms (Fig. 1). He theorized that underpacking was a significant cause of failure and that an abrasive surface on the wire promoted thrombosis. He also used multiple trocar puncture sites, which necessitated a laparotomy to visualize directly the aortic aneurysm. Among six patients who had undergone packing with wire soon after aneurysm rupture, five died within 1.5 years (three within 1 week). Seven patients with unruptured aneurysms died of subsequent hemorrhage, whereas 10 patients survived. Overall, symptoms improved in 15 of 17 patients who had survived the operation. In this series, surgical mortality was 8%.

The London physician Sir D’Arcy Power<sup>23</sup> further improved the packing technique by using a novel wire apparatus. He related aneurysm pain to the lack of sufficient thrombus formation. Coil packing, he postulated, would promote thrombus, decrease the pulsations of the wall against the peritoneum, and reduce pain because “the arterial wall is at rest.” Colt’s apparatus, as Power described it, was invented by a former colleague (G. H. Colt of Aberdeen, Scotland)<sup>9</sup> and consisted of “a trocar and cannula, a ramrod, a tube, and a wisp” (the wisp contained fine steel wires that expanded to form “a miniature umbrella,” Fig. 2).<sup>23</sup> This device was remarkably advanced for the time because it assumed a three-dimensional shape, came pack-




FIG. 1. Illustrations of aneurysm wiring apparatus used by Linton. A: Spool of 200 ft of #30-gauge stainless steel wire Type 302 (18-8), containing 0.08% carbon, 18% chromium, and 8% nickel. The diameter of the wire is 0.01 in. B: Emery cloth used to roughen the wire in increase its surface area. C: Fourteen-gauge 6.5-in Blakemore type of wiring needle and the outer sheath of the trocar. D: Inner sheath to fit the needle featured in C and used to pass the wire into the aneurysm. E: Sharp-pointed stylet to fit the outer sheath featured in C and used to pierce the aneurysm sac. F: Blunt-pointed stylet to fit the inner sheath featured in D and used to push the last end of the wire into the aneurysm. Reprinted with permission from Linton RR: Intrasaccular wiring of abdominal arteriosclerotic aortic aneurysms by the "pack" method. *Angiology* 2: 485-498, 1951.

aged in different sizes, and was rough in texture to promote thrombosis. As the wisps were inserted through a tube into the aneurysm (through direct puncture of the aneurysm wall by using the trocar), they expanded to assume a three-dimensional shape. Power concluded that "wiring" of aortic aneurysms was beneficial because the device "is simple and not attendant of excessive danger . . . [and] well worthy of extended application." His results were less than compelling, however. Of 16 cases he treated until 1921, six patients died in the perioperative period. Note, however, that one patient survived 11 years after wire insertion. Power considered wiring to be a good "method of relieving the pain . . . so constant a feature of the disease," but one that may not alter the natural history of the disease.<sup>23</sup>

In general, results from wire insertion in aneurysms were so poor during the first half of the 20th century that the method was abandoned.<sup>18</sup> Because the survival rate was estimated to be approximately 14%, some physicians claimed the procedure to be useless and possibly a crime to use. Agnew described it as "a rash if not criminal trifling with human life."<sup>26</sup> Ransohoff added that it should be "practised as a last resort" and cautioned against the use of the technique in aneurysms of peripheral vessels, "when so many safer methods are at our command" (he was specifically referring to ligation).<sup>24</sup> In 1916, Rudolf Matas of New Orleans added, "the uncertainties of this method . . . give this procedure the character of pure experiment which is justified solely by the imminent and avoidable danger of death from the progress of the disease itself."<sup>19</sup> Matas also described wire insertion as "semisurgical or quasimedical."

#### *Electrothrombosis (Galvanopuncture)*

In an experimental model in 1824, Scudamore passed a galvanic current through blood, which formed a dense

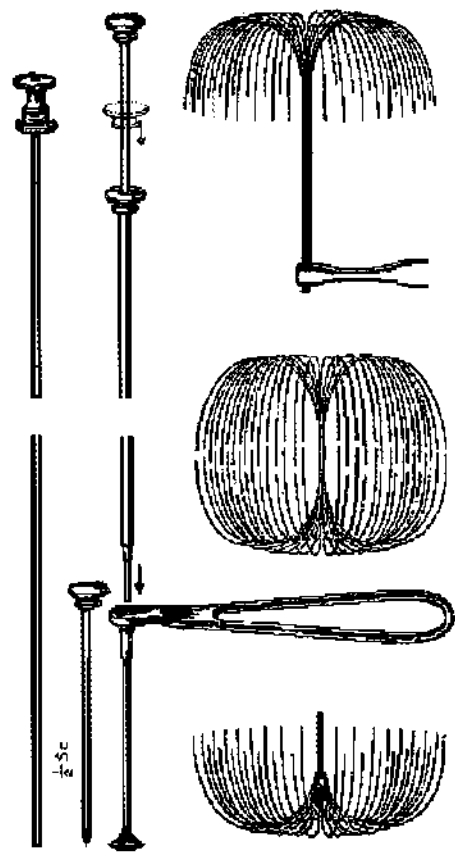


FIG. 2. Colt's apparatus for wire packing of aneurysms. Reprinted from Power D: The palliative treatment of aneurysm by "wiring" with Colt's apparatus. *Br J Surg* 9:27-36, 1921. Copyright British Journal of Surgery Society Ltd. Reproduced with permission granted by John Wiley & Sons Ltd. on behalf of the BJSS Ltd.

black coagulum at the positive electrode.<sup>12</sup> This initial observation was later followed by multiple accounts illustrating the effects of electrolysis on blood coagulation.<sup>5,27</sup> Some attributed the coagulation to inflammation around the electrodes, whereas others theorized that it resulted from the oxidation of blood cells and proteins. Fraser believed that the chemical decomposition of albumin was the primary reason for coagulation from a galvanic current. His assertions were supported by experimental data on electrolysis of egg albumin and other liquids and in vivo data on femoral and carotid artery coagulation in dogs.

As mentioned earlier, Phillips promoted thrombus in the femoral and carotid arteries of dogs by inserting needles through the artery wall. After his initial series of experiments, he "became strongly impressed with the belief, that arteries might be obliterated by galvanic action."<sup>22</sup> He used two needles: "to one of these needles was attached the copper, to the other the zinc pole of a galvanic battery, which consisted of sixteen pairs of two-inch plates; the contact was renewed three several times at intervals of five minutes."<sup>22</sup> After killing the dog, a small coagulum was found around the needles. In a second experiment of this type, the coagulum was thicker and longer and more adherent to the vessel walls. His conclusions reflected his enthusiasm for the procedure:

## Treatment of aneurysms with wires and electricity

I cannot conceal from myself the conviction, that, wherever we find an aneurismal sac, we may with impunity introduce into it attenuated needles, for the purpose of conducting a stream of galvanism, and thereby produce the coagulum of its fluid contents. There is scarcely a part of the animal body which may not be perforated with the most perfect impunity by a very fine needle. . . . If further experience shall confirm the correctness of these observations, I can scarcely conceive the existence of any case of aneurysm which may not be successfully treated by the methods which I have now made known. . . . The extreme simplicity of the operation, the total absence of danger in its application, place it entirely within the power of every practitioner.<sup>22</sup>

Although other physicians, such as O'Shaughnessy (who treated a presumed cervical carotid artery aneurysm in 1842) used galvanic puncture, Ciniselli<sup>7,8</sup> is credited with having popularized the technique.<sup>26</sup> In 1856 he published data from 50 cases involving electropuncture of aortic aneurysms, with a cure rate of approximately 50% and a procedural mortality rate of 14%. His series included four carotid (three deaths), one temporal (cured), and one ophthalmic aneurysm (not cured).<sup>11</sup> Ligation of aneurysms, in comparison, was associated with a mortality rate of 33%. Unlike other authors using electrothrombosis, Ciniselli advocated the use of low electric power and small contact surface area of the electrode with the intent of reducing inflammation of the aneurysm sac.<sup>2</sup> The prevailing theory on electrolysis was "that the acid produced at the positive pole by decomposition of salts in the blood is the agent in coagulating the albumen," although inflammation had a part in maintaining long-term success.<sup>11</sup>

In 1867, Duncan and Fraser<sup>12</sup> described an aortic aneurysm and a cirroid aneurysm of the scalp, which they treated with electrolysis. The thoracic aneurysm was treated using two needles connected to form an electrical circuit (Fig. 3). The first procedure was unsuccessful and therefore repeated. During the ensuing 2 months, however, the patient suffered enlargement of the aneurysm together with repeated hemorrhages and resultant death. Postmortem examination revealed a sac with three ulcerations (presumably from the needle sticks), two of which were plugged with clots. Duncan wrote as follows: "the patient's death was but little if at all delayed by the operation. . . . I have little doubt that even then, had I been able to operate a third time, death by haemorrhage would have been obviated."<sup>12</sup> He concluded that "little danger to the patient is apprehended from the operation. . . . Galvanism in aortic aneurysms is a means of prolonging life in exceptional circumstances."<sup>12</sup> He then related details on a scalp arterial aneurysm, "the shape and size the half of a Jersey pear," which was cured by seven electrolysis operations (two needles connected to four cells of a Bunsen battery for ~20 minutes each). The procedure was complicated by ulceration of the skin (controlled by medical means) and by the patient's intolerance of pain. This case, he conveyed, "is sufficient to establish electrolysis as a valuable therapeutic agent."

As described regarding a scalp aneurysm case by Duncan, electrothrombosis of aneurysms was often painful. Abeille described the procedure as "torture" and sometimes "to cause convulsions and alarming syncope."<sup>11</sup> Additional complications included cauterization of the skin or aneurysm wall, formation of abscess, sloughing of skin, air or fragment emboli, and hemorrhage of the aneurysm sac. In an attempt to reduce complications, many different coatings




FIG. 3. Type of needle use for electropuncture of aneurysms. Reprinted from Duncan J: On the galvano-puncture of aneurisms. *Edinb Med J* 11:920–933, 1866.

on the needles were tried, including varnish, glass, vulcanite, wax, caoutchouc, and gutta-percha. The complication rates associated with these variations in needles were ill defined, however. During the ensuing years, several other physicians reported on electrolysis of aortic aneurysms, but with mixed results. As Holmes summarized, the technique "proves innocent, procures a cure even if temporary, alleviates the patient's sufferings, and prolongs his life," but cautioned that "the circumstances which are favorable to a perfect success occur very rarely in practice."<sup>14</sup> Up to 1873, the use of electrolysis was limited to internal (aortic) aneurysms because of the lack of a better alternative. Holmes cautioned against using electrolysis to treat external aneurysms (such as those of the axillary artery), namely because "for external aneurysms we possess means far more uniform in their action and far more successful" (namely, direct pressure/compression of parent vessel).<sup>14</sup> Rudolph Matas, in 1916, concluded regarding galvanopuncture that they "appeal to us more as placebos than as real remedies."<sup>17,19</sup> Power,<sup>23</sup> who preferred wire insertion, believed that electrolysis only prolonged the operation without altering the physiology of the disease and "seemed reminiscent of a time when little was known of the physiological processes connected with the clotting of the blood." Ransohoff also preferred wire insertion to galvanopuncture and stated that "electrolysis fails, as a rule."

### *Fili-Galvanopuncture (Moore–Corradi Method)*

In 1879 Corradi suggested that an electrical current applied to a permanently inserted metallic coil would combine the dual benefits of wire insertion and electrothrombosis. The merger of Moore's original wire work with the application of electrical current became widely referred to as the Moore–Corradi method.<sup>17</sup> Following Corradi's description, the method was highly regarded and widely applied in North America.<sup>16,17</sup> The procedure was alternatively named the Barwell method because Barwell's 1886 report increased the recognition of the technique.<sup>1,25</sup> The case reported on by Finney,<sup>13</sup> in his 1912 manuscript entitled "The wiring of otherwise inoperable aneurisms," exemplified the status of the Moore–Corradi method at the beginning of the 20th century. He used 10 ft (an arbitrarily determined length, by his own admission) of "75 parts copper to 1000 silver" that was wound tightly around a wooden spool. To this he applied 75 mA electrical current for at least 1 hour. The pain relief was immediate and often occurred with the patient still on the operating table. Of his initial 23 patients, only two were still alive at the time of his publication. He added, however, "when one concluded the absolutely hopeless condition of the patient under any other method of treatment . . . [the results] would seem to justify its employment." Finney asserted that wire insertion could possibly cure saccular aneurysms, but he added that the fusiform variety should not be treated similarly. He also described potential complications, including distal migration of the

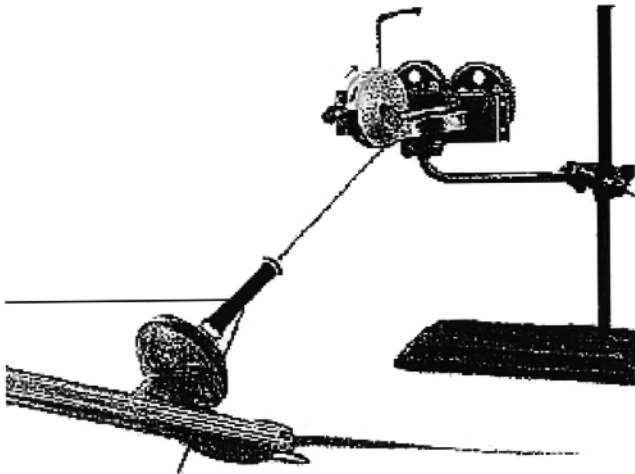


FIG. 4. Passer used by Blakemore and King to wire aneurysms. Reprinted with permission from Blakemore AH, King BG: Electrothermic coagulation of aortic aneurysms. *JAMA* 111:1821–1827, 1938. Copyright© (1938), American Medical Association. All rights reserved.

wires, formation of emboli, end limb ischemia (such as one patient who required arm amputation after ischemia from a migrated wire), sepsis, and formation of distal aneurysms from the alteration in hemodynamics. Over the years, the Moore–Corradi method was tried by many authors, often with failure. For instance, Corson<sup>10</sup> attempted to treat an ascending aorta aneurysm by using silver wire and electricity. Although a thrombus formed, the patient died days later. He concluded that potential existed in the treatment, but the immaturity of the technique precluded better results.

In 1938, relating the disappointing and often variable results achieved with aneurysm wire insertion up to that time, Blakemore and King improved on the Moore–Corradi method. They proposed that the lack of success was attributable mainly to an underestimation of aneurysm size and hence incomplete wire insertion. Consequently, they described a novel method of determining the amount of wire required to achieve thrombosis. Instead of the size of the aneurysm, they used blood velocity as a guide to the amount of wire required. Using an alloy of 90% silver and 10% copper that was coated with enamel, they introduced 33 ft of wire into aneurysms and heated it to 80°C. They used a newly designed wire passer that distributed the 33-ft segments in loops within 4 minutes (Fig. 4). After the initial heating, the wire was reheated. Then, using the diminished current required to reheat the wire to the same temperature as the first, the authors estimated the number of 33-ft segments of wire necessary to completely pack the aneurysm.<sup>3,4</sup> The rationale was that the rate of cooling of the first segment of wire inserted was related to the velocity of blood flow. “On the basis of the number of amperes of current required to heat the first 33-foot segment of wire to 80C, it is possible to determine . . . approximately the amount of wire that will be necessary to impede the blood flow.”<sup>3</sup> They used a mean of 118 ft of wire. They also advocated heating the wire to promote inflammation and repeating the wiring at 10- to 14-day intervals. Of the 11 reported cases, their results were mixed. Seven patients were alive (longest follow up of 3.5 years), with six having complete

relief of symptoms. They also treated a symptomatic cavernous sinus aneurysm by inserting the wire through the orbit.

Although the results of the Moore–Corradi method were mixed, the technique gained popularity. Many researchers recommended the treatment only as a last resort, however. Nonetheless, the concept of treatment through complete packing of the aneurysm, with or without electrical current, was strengthened.

#### Further Evolution

Following in the footsteps of these ingenious pioneers, several neuroradiologists and neurosurgeons in the 1960s and 1970s were encouraged to seek therapeutic alternatives to surgery in the treatment of intracranial aneurysms.<sup>15</sup> These more recent efforts were facilitated by the development and widespread acceptance of cerebral angiography and the availability of newer and safer endovascular catheters. In 1965 Mullan, et al.,<sup>21</sup> reported inducing electrothrombosis in 12 patients with intracranial aneurysms. This was accomplished by passing electric current through an electrode needle introduced into the aneurysm through a burr hole. The partial success of Mullan and coworkers with this technique paved the way to today’s developments.

#### Conclusions

Wire insertion alone, galvanopuncture (electrothrombosis), and fili-galvanopuncture (wire insertion together with electrothrombosis) were commonly described in the surgical literature during the 19th and early 20th centuries. Initially, most investigators advocated their use only as palliation in the treatment of patients with life-threatening aneurysms. As the treatments evolved, however, the enthusiasm for potential cure increased. Electrolysis and wire insertion were considered to be alternatives to the existing but limited choices of medicinal management and ligation. Gradually, the techniques were regarded as a viable option in the treatment of a disease considered universally fatal. With further advances in catheters and imaging, the basic principles conceptualized and practiced by these ingenious pioneers led to the acceptance of endovascular treatment of aneurysms.

#### References

1. Abbe R: Aneurisms treated by the introduction of catgut, or of wire, with electricity. *Ann Surg* 6:307–317, 1887
2. Beck M: Aneurism of the descending aorta treated by galvanopuncture. *Lancet* 2:550–552, 1873
3. Blakemore AH: Progressive constrictive occlusion of the abdominal aorta with wiring and electrothermic coagulation. A one-stage operation for arteriosclerotic aneurysms of the abdominal aorta. *Ann Surg* 133:447–462, 1951
4. Blakemore AH, King BG: Electrothermic coagulation of aortic aneurysms. *JAMA* 111:1821–1827, 1938
5. Bowditch HI: Thoracic aneurism treated by electrolysis, with remarks thereupon. *Boston Med Surg J* 94:58–67, 1876
6. Christian HA: Aneurysms of the thoracic aorta treated by wiring. *Boston Med Surg J* 166:122–127, 1912 (reference unverified)
7. Ciniselli L: Osservazione di aneurismi dell’ aorta trattati coll’ elettropuntura. *Adunanze dell’ Accademia* 12:418–430, 1872
8. Ciniselli L: Sulla elettro-puntura nella cura degli aneurismi. *Gazzetta Medica di Milano* 6:9–14, 1847 (reference unverified)

## Treatment of aneurysms with wires and electricity

9. Colt GH, Marshall CJ, Wakeley CPG: Three cases of aneurysm of the aorta treated by wiring. **Br J Surg** **13**:109–119, 1925
10. Corson ES: A case of thoracic aortic aneurysm treated by the introduction of silver wire with electricity. **Philadelphia Med J** **3**: 511–512, 1899
11. Duncan J: On the galvano-puncture of aneurisms. **Edinb Med J** **11**:920–933, 1866
12. Duncan J, Fraser TR: On the treatment of aneurism by electrolysis: with an account of an investigation into the action of galvanism on blood and on albuminous fluids. **Medico-Chir Soc Edinb Med J** **13**:101–120, 1867
13. Finney JMT: The wiring of otherwise inoperable aneurysms. With the report of cases. **Ann Surg** **55**:661–681, 1912
14. Holmes T: The surgical treatment of aneurism in its various forms. **Lancet** **2**:583–586, 1873
15. Hopkins LN, Lanzino G, Guterman LR: Treating complex nervous system vascular disorders through a “needle stick”: origins, evolution, and future of neuroendovascular therapy. **Neurosurgery** **48**:463–475, 2001
16. Hunner GL: Aneurism of the aorta treated by the insertion of a permanent wire and galvanism (Moore-Corradi method). **Bull Johns Hopkins Hosp** **11**:263–279, 1900
17. Keen W, DaCosta J (eds): **Surgery Its Principles and Practice**. Philadelphia: WB Saunders, 1916
18. Linton RR: Intrascular wiring of abdominal arteriosclerotic aortic aneurysms by the “pack” method. **Angiology** **2**:485–498, 1951
19. Matas R: The treatment of abdominal aortic aneurism by a preliminary exploratory celiotomy and peritoneal exclusion of the sac, followed at a later sitting by wiring and electrolysis, with the report of two hitherto unpublished cases. **Trans South Surg Gynec Assoc** **13**:272–330, 1901
20. Moore CH, Murchinson C: On a new method of procuring the consolidation of fibrin in certain incurable aneurysms: with the report of a case in which an aneurysm of the ascending aorta was treated by the insertion of wire. **Proc Roy Med Chir Soc London** **4**:327–335, 1864 (reference unverified)
21. Mullan S, Raimondi AJ, Dobben G, et al: Electrically induced thrombosis in intracranial aneurysms. **J Neurosurg** **22**:539–547, 1965
22. Phillips B: **A series of experiments performed for the purpose of showing that arteries may be obliterated without ligature, compression or the knife**. Pamphlet published in London, Longman & Co, London, Churchill, 1832 (reference unverified)
23. Power D: The palliative treatment of aneurysm by “wiring” with Colt’s apparatus. **Br J Surg** **9**:27–36, 1921
24. Ransohoff J: A case of aortic aneurism treated by the insertion of wire. **JAMA** **7**:481–485, 1886
25. Rosenstim J: The surgical treatment of aneurism of the arcus aortae, with a case cured by the Loreta-Barwell method. **Am J Med Sci** **101**:55–58, 1891
26. Schechter DC: Flashbacks: electrical treatment of aneurysms. **PACE** **2**:234–245, 1979
27. Smith S: Case of aneurism of aorta-treatment by galvano-punctures: result encouraging. **Bristol Med Surg J** **4**:233–242, 1886
28. Stewart DD: Final report of a case of a very large innominate aneurysm completely cured by the employment of electrolysis through ten feet of snarled, coiled, fine gold wire, introduced through the sac: Death at the expiration of three and a half years from cerebral thrombosis. **Br Med J** **2**:387–390, 1897
29. Stewart DD, Salinger JL: On the treatment of aneurism by electrolysis through introduced wire: report of a successful case. **Am J Med Sci** **112**:170–177, 1896
30. Velpeau A: Memoire sur la piqure ou l’acupuncture des arteres dans le traitement des anevrismes. **Gaz Med Paris** **2**:1–4, 1831 (unverified)
31. Weir RF, Page ED: Aneurysm of the ascending aorta treated by Macewen’s needling method for inducing a white thrombus. **NY Med J** **55**:510–511, 1892

---

Manuscript received May 8, 2003.

Accepted in final form July 31, 2003.

Address reprint requests to: Giuseppe Lanzino, M.D., Department of Neurosurgery, University of Illinois College of Medicine at Peoria, 530 NE Glen Oak Avenue, Peoria, Illinois 61637. email: Lanzino@uic.edu.